

# Natasha Demkina

## *The Girl with Normal Eyes*

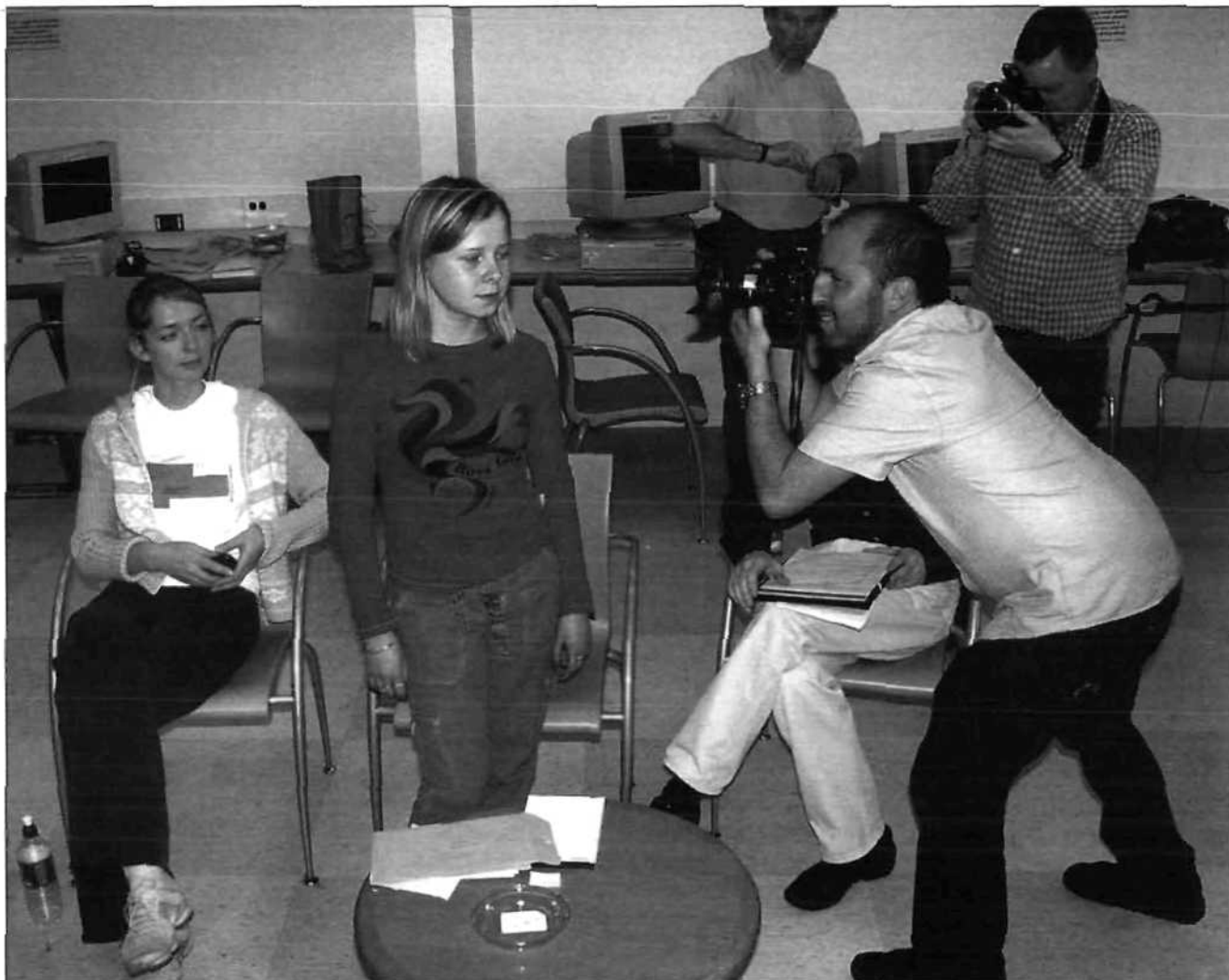
.....

*Many people in Russia and the United Kingdom believe a teenage girl can identify diseases in patients better than their physicians. Investigators who tested the medical psychic for a Discovery Channel program don't agree.*

ANDREW A. SKOLNICK

One hundred ten years ago, German physicist Wilhelm Roentgen announced the discovery of an invisible form of radiation that could make photographs of bones and organs inside a living human body. At first, many scientists called the discovery of mysterious "X-rays" a hoax, but when the skeptics put Roentgen's claims to the test, they were quickly convinced about one of the greatest discoveries in science and medicine. Indeed, just six years after his discovery, Roentgen was awarded the first Nobel Prize in physics.

Now comes a teenage girl from Saransk, Russia, who claims to have X-ray-like vision that lets her see inside human bodies. And she uses this vision to make medical



After the CSICOP-CSMMH test of Natasha Demkina, a Discovery Channel photographer takes publicity shots for *The Girl with X-ray Eyes*. The program, already broadcast several times in Europe and Asia, has never been shown in North America. The author believes the program may be considered too skeptical for a more credulous American audience. Photo credit: Andrew A. Skolnick

diagnoses that, she claims, are often more accurate than those of doctors. Widely hailed in Russia as “the girl with X-ray eyes,” seventeen-year-old Natasha Demkina has a growing number of patients, doctors, journalists, and others who are convinced her powers are real.<sup>12</sup> That following is proving lucrative for Natasha and her family. The young psychic reportedly charged about \$13 per reading and provided about ten readings each weekday night. That income, about \$2,600 a month, is more than forty times the average monthly income of government workers in Saransk.

In March 2004, Monica Garnsey, the producer-director of a Discovery Channel documentary on Natasha, asked the Committee for the Scientific Investigation of Claims of the Paranormal (CSICOP) to scientifically test the young woman's claims for the program. Because Natasha's paranormal claims involved medical diagnoses, I was asked to join CSICOP fellows Ray Hyman and Richard Wiseman in designing an appropriate preliminary test, to see if the medical psychic's abilities war-

ranted further study. (Hyman's accompanying article, “Testing Natasha,” is the report of those tests.)

Examining the claims of medical psychics like Natasha Demkina presents unique difficulties beyond the usual problems involved in testing dowsters, mind readers, and most other paranormal claimants. For example, we needed to consider the logistical, legal, and ethical concerns regarding the privacy of subjects' medical information. Barrie Cassileth, chief of Integrative Medicine Service and the Laurance S. Rockefeller Chair in Integrative Medicine at Memorial Sloan-Kettering Cancer Center, was willing to help us recruit volunteer subjects through the Center. However, the Center declined involvement in the

---

*Andrew A. Skolnick is the executive director of the Center for Inquiry's Commission for Scientific Medicine and Mental Health. An award-winning medical journalist, Skolnick worked for nearly nine years as an associate editor of the Journal of the American Medical Association. E-mail: askolnick@centerforinquiry.net.*

CSICOP and CSMMH  
Preliminary Test of Natasha Demkina

This subject had his or her appendix surgically removed. The appendix is a small finger-size tube attached to the large intestine, near where it joins the small intestine.

Russian: У данного субъекта удален аппендикс хирургическим путем.  
Аппендикс - это маленькая трубка размером с палец, которая соединяет  
ея с толстой кишкой там, где она соединяется с малой кишкой

The subject with this medical condition is number (circle the correct number):

Russian: Субъект, у которого данная медицинская проблема - аппен-  
дикс правый или левый

1 (2) 3 4 5 6 7

Sign your name:

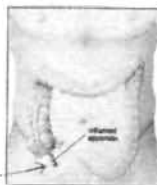Russian: Подпишитесь.

Test proctor's signature:

Russian: Подпись медицинского субъекта

Date: May 1, 2004 - Дата: 1 мая 2004 г.

Russian:



This is one of the six test cards that were used to assess Natasha's ability to see abnormalities within the subjects' bodies. In English and in Russian, the card directed Natasha to identify the number of the subject who doesn't have an appendix. Natasha answered subject number 2—a woman who still has her appendix. Natasha protested during the test that appendixes can grow back after an appendectomy. When told this isn't possible, she insisted that they do grow back in Russia. Photo credit: Andrew A. Skolnick

documentary, so Cassileth could only assist us unofficially by recruiting four of the seven volunteers we needed from her personal acquaintances.

We wanted a test that would prevent Natasha from making diagnoses that could not be disproved, as is her usual practice. So we settled on a simple test design that required Natasha to find already established medical abnormalities in the test subjects. This not only eliminated the problem of her giving us a long list of health problems that cannot be disproved, it eliminated the problem of subjects trying to force Natasha's vague comments to fit their existing problems. And it prevented the potential harm that could result from subjects being frightened into undergoing unnecessary and invasive medical tests to rule out diseases that Natasha claims to see.

Such a calamity happened to Dr. Christopher Steele, the host of a medical television show in the United Kingdom, who in 2004 invited Natasha on his show to provide "medical readings." When she read Steele, she said she saw something wrong with his gall bladder and that he had kidney stones and an enlarged liver and pancreas. The physician rushed off to have a battery of expensive and invasive clinical tests—which found nothing wrong with him.<sup>3</sup> In addition to being exposed to unnecessary diagnostic radiation, he had a colonoscopy, which is not without risks. Studies have found that .2 percent (two tenths of one percent) or more of patients who undergo colonoscopic screening suffer a bowel perforation, which can lead to life-threatening infection and the need for surgery.<sup>4,5</sup>

We wanted to conduct a blinded test. Natasha claims to see through people's clothing, yet she says she cannot see through a fabric screen, which we wanted to use to prevent her from seeing the test subjects. We found this unexplained contradiction curious—and frustrating: Any test she would agree to would have to allow her to study the test subjects using her normal senses. As Hyman points out, this study flaw alone could provide an astute person powerful clues about a person's health problems. It would be less of a problem if we were able to recruit subjects who were physically and demographically similar. Unfortunately, we had great difficulty recruiting subjects for the test and had to settle for several people with characteristics that suggested their target conditions.

Natasha claims she can see everything inside of people's bodies down to the cellular level, and her mother says her readings are 100 percent accurate. So the test—which required her to match at least five of the target medical conditions to the correct subjects—should have been very easy compared with her normal readings. She didn't have to scan entire bodies looking for unknown conditions. She was told exactly what to look for and exactly where to look. Yet it took her more than four hours to complete the test and, inexplicably, she took an hour to examine the seven subjects before deciding which one was missing a large part of her left lung! She guessed that one correctly, but why would anyone who claims to be able to see "every cell" inside a person take an hour to decide which person was missing a large portion of one lung?

Natasha matched only four of the conditions correctly—a score that everyone prior to the test had agreed would not justify further testing. Natasha's most dramatic misdiagnosis was her failure to see a large metal plate covering a missing section of skull in a man who had a large brain tumor removed. Instead, she indicated that she "saw" a metal plate and missing skull section in a man who had his appendix removed but a normal skull.

There was an error in our test protocol, which could have been much more embarrassing for us, had Natasha had the power to see it. Although our test design<sup>6</sup> required no more than one subject to have any of the target medical conditions, we discovered after the test was over that the man who had a metal plate in his head also had undergone an appendectomy. He had forgotten to mention this when he was recruited but brought it up after the test because a missing appendix had been one of the test target conditions. This mistake gave Natasha twice the chance of correctly guessing which subject was missing his or her appendix. Despite having twice the odds of being correct, she still chose a subject with an intact appendix.

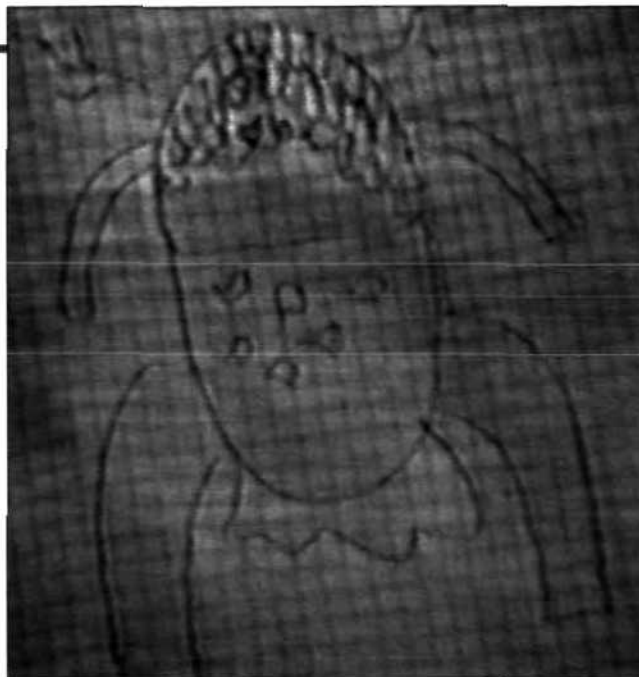After the test, Natasha asked if she could give me a medical reading in the hope of convincing me that her powers are real. With CSICOP's Senior Research Fellow Joe Nickell taking notes, I agreed. Her reading, in which she scanned me from head to toes while describing the abnormalities she saw, took

about ten minutes. Few of my organs passed the inspection: My neck vertebrae were too tight, too close. The bronchial tubes of my lungs had phlegm causing me to cough. The muscle on the left side of my heart is a bit weak and the valve closes late. The mucosa of my stomach is abnormal. A segment of my liver was enlarged and I was suffering poor bile circulation. The head of my pancreas is increased and abnormally dark (although not seriously). My duodenum has a little scar. My prostate gland has a nodule and is inflamed. My right kidney has "sand," while my left kidney's urethra is enlarged. In other words, I should forget about ever again signing an organ donor card.

Neither my physician nor I are aware of *any* of these problems. Nevertheless, Natasha and her supporters claim she sees what doctors and their tests often miss. The only way I could prove her wrong would be to submit to an autopsy—which I'm not quite ready to do.

I believe Natasha may have been making some bad guesses based on non-paranormal observations. While the test was ongoing, I swallowed some water down my wind pipe, which triggered a loud fit of coughing. It was so loud that someone had to close the briefing room door. Natasha apparently misjudged the cause of my coughing. My shoulders and neck were sore and tired from lugging around my luggage and a heavy camera bag. She apparently misread my drooping posture as a sign of a spinal problem. And earlier, I had complained to the Russian translator that I had a headache (from stress and lack of sleep). I suspect that information may have been passed on to Natasha, who wrongly attributed the problem to narrowed blood vessels in my neck. Even more telling was what Natasha didn't "see." She failed to point out any of my confirmed health problems, which include hypertension, hypercholesterolemia, recent colon surgery, nasal polyps, a very narrow pharynx, and sleep apnea. She also didn't see the calcified plaque in two of my coronary arteries that was documented by spiral CT scan.

The Discovery Channel program, *The Girl with X-ray Eyes*, has already been broadcast several times over the past six months in Europe and Asia,<sup>7</sup> but has not been broadcast in North America. The program highlights one of Natasha's most impressive diagnoses, involving a man who says he had been treated for tuberculosis for a year yet hadn't gotten any better. In desperation, he turned to Natasha for help. Unable to describe what she saw in



Natasha Demkina supporters widely cite this "diagnostic" drawing of a "sarcoidosis granuloma" as evidence of her remarkable "X-ray" vision. Yale Rosen, M.D., a leading expert on sarcoidosis granuloma, however, disagrees. Frame from the Discovery Channel program *The Girl with X-ray Eyes*. ©2004 Discovery Channel

the man's lungs, she drew a picture. With the help of Natasha's drawing, the man got a referral to a doctor in Moscow, who claimed to see the same thing through her microscope and that the drawing is indicative of an inflammatory disease lesion called sarcoidosis granuloma. That's a remarkable confirmation of the young psychic's powers—at least for viewers who don't have a clue what sarcoidosis granulomas look like.

It didn't look like any pathological finding I've seen, so I sent an image of the drawing to Yale Rosen, M.D., Professor of Pathology at SUNY Downstate Medical Center, a leading expert on sar-

coidosis granuloma, whose *Atlas of Granulomatous Diseases* is widely used in the training of pathologists.<sup>8</sup> Here is Dr. Rosen's opinion of Demkina's drawing:

Try as I might I can see no resemblance whatsoever of this drawing to a granuloma or to any other microscopic pathologic finding that I know of. If I were presented with this drawing and no background history I would guess that it was made by a 4–6 year old child who was trying to depict a human-like head with four appendages (? arms and legs) attached. If Ms. Demkina is claiming that a physician made a diagnosis of sarcoidosis based upon this drawing I would say that that's simply unbelievable.

We've asked the producer/director several times when the documentary may be broadcast in the United States. We have not received an answer. I am afraid that Discovery Channel may consider the program too skeptical for the American audience. I hope I will be proven wrong.

## Notes

1. Moniche, Igor. 2004. X-ray girl sees right through Sun man. *The Sun*. Available at [www.satori-5.co.uk/word\\_articles/misc/xray\\_eyes.html](http://www.satori-5.co.uk/word_articles/misc/xray_eyes.html).
2. Hagan, Lucy. 2004. Girl "sees" broken bones. *The Sun*. Available at <http://groups.msn.com/Mindtalk/itspossible.msnw>.
3. TV doctor in health scare after meeting "X-ray vision" girl. 2004. *Ananova*. Available at [www.ananova.com/news/story/sm\\_860742.html?menu=news.scienceanddiscovery](http://www.ananova.com/news/story/sm_860742.html?menu=news.scienceanddiscovery).
4. Kavic, S.M. and M.D. Brasson. 2001. Complications of endoscopy. *American Journal of Surgery*. April; 181(4):319–32.
5. Anderson, M.L. et al. 2000. Endoscopic perforation of the colon: lessons from a 10-year study. *American Journal of Gastroenterology* December; 95(12):3418–22.
6. Test Design and Procedures for Preliminary Study of Natasha Demkina. 2004. CSICOP and CSMMH. Available at [www.demkina/demkina.protocols.doc](http://www.demkina/demkina.protocols.doc).
7. *The Girl with X-ray Eyes*. 2004. The Human Files series, Discovery Channel. Program description available at [www.discoverychannel.co.uk/humanfiles/feature2.shtml](http://www.discoverychannel.co.uk/humanfiles/feature2.shtml).
8. Rosen, Yale. *Atlas of Granulomatous Diseases*. Available at [www.granuloma.homestead.com](http://www.granuloma.homestead.com). □